

PHE National Parasitology Reference Laboratory, Hospital for Tropical Diseases, 3rd Floor Mortimer Market, Centre, Capper Street, London WC1E 6JB, TEL: +44 (0) 207 383 0482, FAX +44 (0) 207 388 8985

Chilomastix mesnili

Chilomastix mesnili is of cosmopolitan distribution although found more frequently in warm climates. It is thought to be non-pathogenic although the trophozoite has been associated with diarrhoeic stool.

Morphology of the cyst

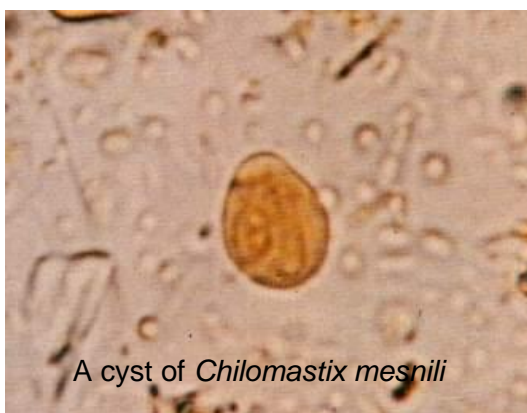The cyst is 6-9µm It has a large single nucleus with a large karyosome. It has a prominent side knob which gives it a characteristic lemon shape. The cytosome is evident with a curved shepherd's crook fibril.

Morphology of the trophozoite

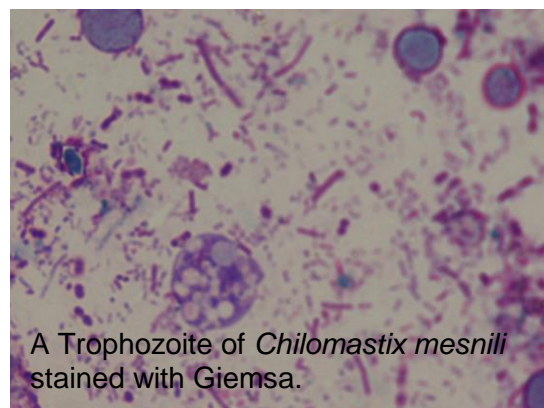
The trophozoites of *C. mesnili* are pear shaped and measure 10-20µm in length. It has 1 large nucleus with a small karyosome and 3 flagella which extend from the nucleus at the anterior end of the parasite. A distinct oral groove or cytosome can be seen near the nucleus It moves in a directional manner.

Laboratory diagnosis

The characteristic lemon shaped cysts can be seen in a formol-ether concentrate. Motile organisms can be seen in a wet preparation of a fresh stool however the characteristic morphology is evident in a permanently stained preparation.



A cyst of *Chilomastix mesnili*



A Trophozoite of *Chilomastix mesnili* stained with Giemsa.